Mix tumor of submandibular gland

Dr. Besim Boci

Dr. Besim Boci[1], Prof.Pjerin Radovani[2], Dr. Konstandin Balloma[3], Dr. Roven Sinani[4]
[1,2]University Hospital Center of Tirana, ENT Service, [3]Private Clinic in Greece, ENT Surgeon
[4]Civil Hospital of Gjirokastra, ENT Surgeon

Summary

This report of a mix tumor of the submandibular gland appeared to be a very interesting case due to the fact that it was only the heavy weight of the mass the reason why the patient came for medical treatment. Through discussing the case we may recall briefly some aspects of the clinical, histological and the treatment of these mix tumors, along with the possible metastasis and recurrences.

The patient, LK, 82 years old, was admitted on the ENT clinic, Tirana University Hospital centre on the 15th of June, 2007.

The diagnosis was Submandibular tumor. His main complain was the weight of the mass. The tumor was removed under general anesthesia and was sent for histological examination. The latter showed a mix tumor of the gland.

Introduction

Tumors of the salivary glands are often encountered in the head and neck surgical practice. They represent 0.1-2% of all tumors in general, and 5% of tumors in head and neck regions. Among tumors of salivary glands the most frequent are mix tumors and pleomorphic adenomas[1,2,3].

The purpose of this article is to present a clinical case of a mix tumor of the submandibular gland with a gradual growth and the patient that seek medical help only because of the big mass and weight of the tumor mass.

Case presentation

Laze Kabadhi, aged 82, was admitted in the ENT clinic of the University Hospital Centre of Tirana (UHCT - QSUT) on 15.06.2007 with the diagnosis "Tumor regionis submandibularis sin". General complaints of the patient were: a mass under the mandible and the sense of weightiness on the side of the tumor (Picture 1).

The tumor appeared for the first time eight years ago and has since been progressively growing, till it reached the size of a child's head. The patient seeked medical help because he could not bear the weight of the tumor anymore. The physical examination showed a tumoral mass in the left submandibular region, that went down to the clavicle, mobile, nodular, and with strong consistence in palpation. Nothing of importance was found from other organs. CT scanner confirmed the presence of a solid formation with regular and polycystic contours, with a dimension of 110-90-80 mm. Fine needle biopsy examination of the tumoral mass was positive for a mix tumor.

Picture 1. *Submandibular tumor.*

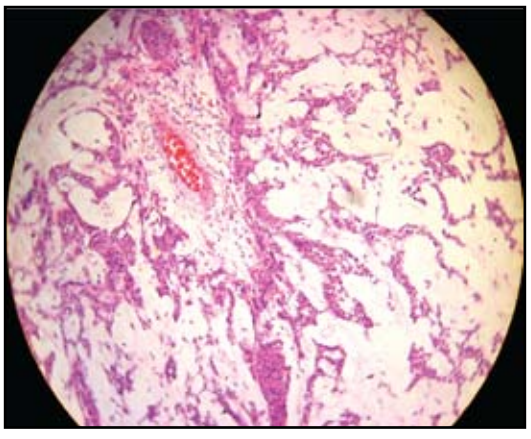

Picture 2. *Histopaphological findings of the submandibular tumor.*

The patient underwent the surgical intervention that was finalized with the extraction of the tumoral mass and spearing the mandibular branch of the facial nerve. The intervention findings showed a mass with the same dimensions as described by the CT scan, with a hard and strong consistence, gray-whitish colored and well encapsulated. Findings from the histopaphological examination of the mass proved that we had to do with a mix tumor of the submandibular glad (Picture 2). Two months after the intervention the patient was in good condition.

Case discussion

It is well known that there is an interrelation between tumors of the salivary glands. So, the interrelation between parotid and submandibular glands is around 100/10, while the malignity rate varies between 26% and 50%[4].

Our study case was a mix tumor, term used randomly in our country, also defined as "polymorphic adenoma", but the favorite term remains a personal choice[5]. They are called mix tumors because of the morphological varieties, including both connective and epithelial tissue elements. Mix tumors are more frequent in big salivary glands, but they can also originate from small salivary, the upper respiratory and digestive tracts[6,7].

The majority of submandibular tumors are presented as slow-growing indolent masses, under the angle of the mandible. Benign tumors are often in women and malignant tumors in men. The most frequent benign tumor is the mix tumor, while adenocystic carcinoma is the most frequent malignant one. Benign tumors are found in the IV-V decade, and malignant ones in the VI decade. Malignancy is suggested by the fixation of the mass and the appearance of neck lymph nodules.

Fine needle biopsy has no decisive role in setting the diagnosis. However it helps in 85% of the cases[1,8].

CT Scan and MRI are the newest diagnostic practices in our country, however in our case we could determine only the demarcation of the tumor, but other clinical study groups have not been able to differentiate benign from malignant tumors[4].

Final diagnosis remains the histopathological examination. Morphologically, mix tumors consist of epithelial elements that can take the form of ducts, alveoli and myoepithelial cells that exert as plasmocytic, fibrocolagenic or mixochondroid cells, which are compatible with the histopathological findings of our case.

The treatment included the total resection of the submandibular gland, in order to avoid recurrences. So, an "in toto" resection is required, without touching the tumoral capsule. If in the case of a rupture of parotid mix tumors the recurrence is to be discussed[9,10], in the case of a rupture of submandibular mix tumors the recurrence is certain[4,5]. When mix type of pleomorphic adenomas dominates, the risk of recurrences is much higher[11].

Malign transformation of mix tumors is rare and more often in patients that have been diagnosed or treated at a late stage of the disease. The risk of malignant transformation in the first 5 years is 1.5%, but it can grow up to 10% when the tumor has a 15 years old

history. On some few cases the tumor can metastasize, but should not be confused with malignant mix tumors[12].

Literature describes these tumors as tumors with different dimensions, which rarely reach the size of an orange. But in our case study the patient had a tumor of much higher dimensions that can be compared with the head of a child. Because of the old age and the big fear the patient had, he hesitated to see a specialist until the weight of the tumor became unbearable for him.

Bibliography

1. Radovani P., Shameti S.: Tumoret mikste te gjndrave te peshtymes. Revista Mjeksore 1985; 4:35-41.
2. Trimcev S.: Mbi kirurgjine e tumoreve mikste te gjendrave te peshtymes. Buletin i Shkencave Mjeksore 1973; 1:151-161.
3. Goh Y.H., Sethi D.S.: Submandibular gland excision; a five-year review. Tha Journal of Laryngology and Otology 1998; 112:269-274.
4. Bradley P.J.: Submandibular gland and minor salivary gland neoplasms. Current Opinion in Otolaryngology, Head and Neck Surgery 1999; 7:72-79.
5. Bradley P.J.: Recurrent salivary gland pleomorphic adenoma: etiology, management, and results. Current Opinion in Otolaryngology, Head and Neck Surgery 2001; 9:100-108.
6. Becelli R: Pleomorphic adenoma of the lachrymal gland, J Craniofac Surg 13:49-51, 2002.
7. Carew JF: treatment of recurrent pleomorphic adenomas of the lachrymal gland, Otolaryngol Head Neck Surg 121: 539-542, 1999.
8. Atula I., Grenman M., Lappala P. et al.: Fine needle aspiration cytology of submandibular gland lesion. The Journal of Laryngology and Otology 1995; 109:853-858.
9. Henriksson G., Westrin K.M., Carlsoo B. et al.: Recurrent primary pleomorphic adenomas of salivary gland origin. Cancer 1998; 82:617-618.
10. Buchman G., Stringer S.P., Mendenhall W.M. et al.: Pleomorphic adenoma: effect of tumor spill and inadequate resection on tumor recurrence. The Laryngoscope 1994; 104:1231-1234.
11. Stennert E., Wittekindt C., Klussmann J.P.: Recurrent pleomorphic adenoma of the parotid gland. The Laryngoscope 2004; 114: 158-163.
12. Bradley P.J.: Metastasizing pleomorphic salivary adenoma' should now be considered a low-grade malignancy with a lethal potential. Current Opinion in Otolaryngology, Head and Neck Surgery 2005; 13: 123-126.
13. Chandrasekhar J, Farr DR: Pleomorphic adenoma of the salivary gland, Br J Oral Maxillofac Surg 39: 390-393, 2001.
14. Glas AS: Surgical treatment of recurrent pleomorphic adenoma of the parotid gland, Head Neck 23: 311-316, 2001.
15. Batsakis JG, Luna MA: Basaloid monomorphic adenomas, Ann Otol Rhinol Laryngol 100:687-690, 1991.
16. Stennert E: Histopathology of pleomorphic adenoma in the salivary glands.